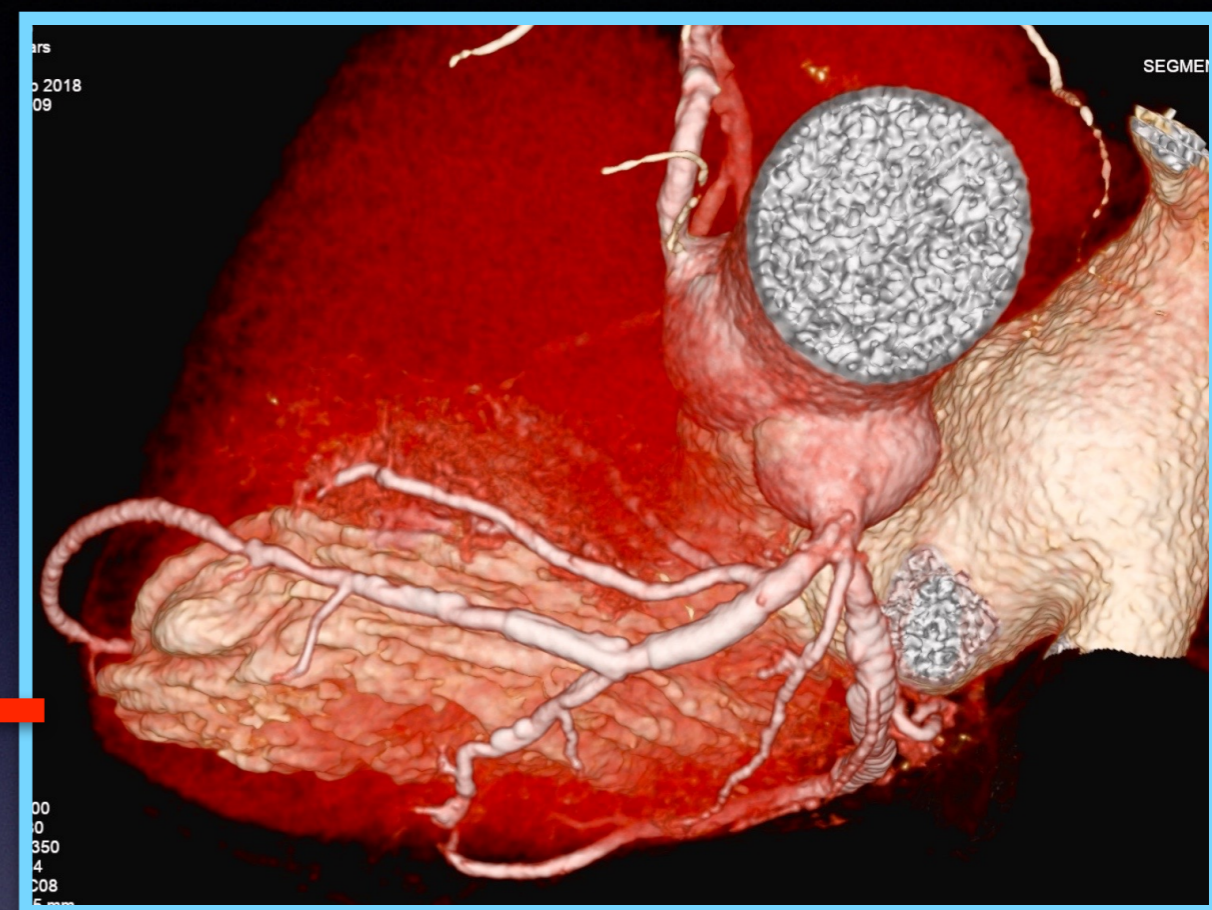
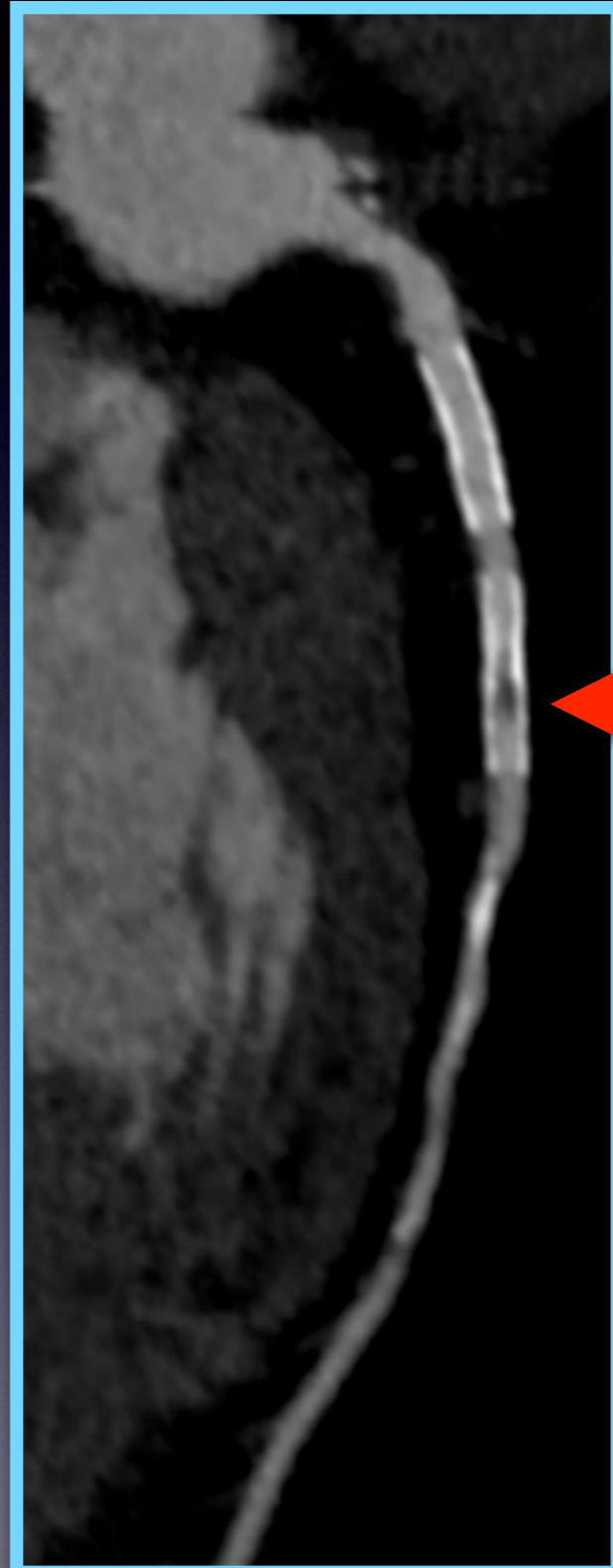
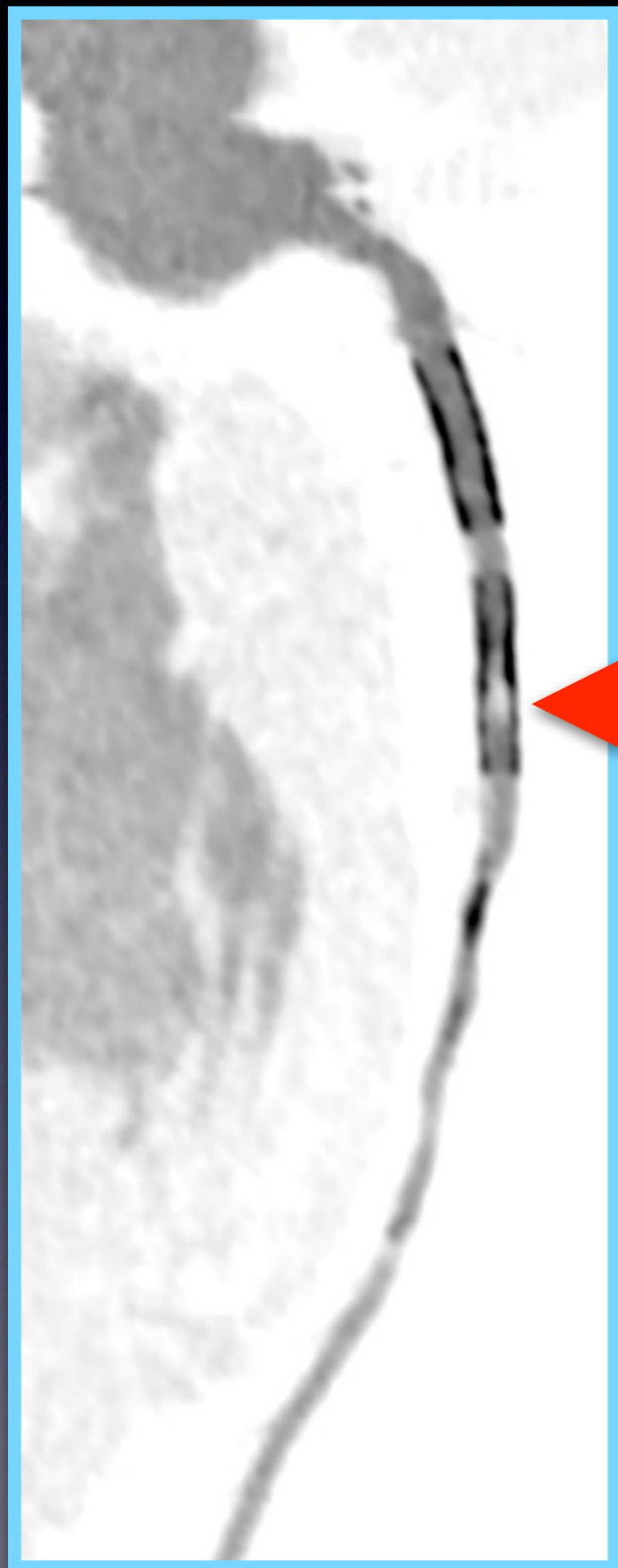


In Stent Restenosis



**Restenosis in the more
distal stent
of the
Anterior Descending
Artery**